

# The Postauricular Fascial Flap as an Adjunct to Mustardé and Furnas Type Otoplasty

Nigel Horlock, F.R.C.S., Alok Misra, F.R.C.S., and David T. Gault, F.R.C.S.

Northwood, United Kingdom

Anterior riberation methods of otoplasty have been criticized because of the risk of anterior hematoma that can cause anterior skin necrosis, scarring, and even cartilage destruction caused by infection. As a result, cartilage-sparing otoplasty such as the Mustardé and Furnas types has been increasingly popular. However, postauricular suture extrusion may result, and recurrence rates of up to 25 percent have been recorded. In this study, cartilage-sparing otoplasty is refined by the addition of a postauricular fascial flap to reduce suture extrusion and recurrence rates. Fifty-one patients underwent otoplasty (45 bilateral, six unilateral). This technique involves the elevation of a fascial flap from the postauricular region. A new antihelical fold is then created by Mustardé sutures, and the conchal bowl is rotated by Furnas-type concha-mastoid sutures. The fascial flap is then advanced to cover the sutures with a supplementary vascularized layer to prevent suture extrusion. In addition, the advancement of the flap acts as a postauricular support to prevent recurrence. A natural-looking antihelical fold and helical rim is created by this technique. There were no hematomas. There was recurrence in eight ears (8 percent) in six patients. Two patients requested further surgery. No patients developed suture extrusion or granuloma. This is a simple and intrinsically safe procedure and does not cause irreparable complications such as anterior scarring or skin necrosis. The postauricular fascial flap seems to prevent suture extrusion. It may also help to reduce recurrence rates to acceptable levels. (*Plast. Reconstr. Surg.* 108: 1487, 2001.)

Otoplasty techniques can be divided, in general, into cartilage-cutting and cartilage-sparing methods. It would seem that, of the cartilage-cutting procedures, the anterior riberation method is most commonly used.<sup>1,2</sup> However, there has been increasing criticism of this method because of unacceptably high complication rates, especially in training-grade surgeons.<sup>3</sup> These complications arise from the anterior dissection causing anterior hematoma that may lead to anterior skin necrosis. Chon-

dritis may follow this condition, and this may result in irreparable cartilage irregularities.

As a consequence, it has been suggested that there has been a trend away from cartilage-cutting methods and an increasing popularity of cartilage-sparing techniques in which the auricle is medialized by sutures.<sup>2,4</sup> Of these, the Mustardé or Furnas concha-mastoid sutures are the most commonly described.<sup>5,6</sup> However, postauricular suture extrusion may result, or there may be pain from nonabsorbable sutures prickling the dermis from beneath.<sup>7</sup> Furthermore, recurrence rates of up to 24 percent have been recorded.<sup>8</sup>

In this study, a postauricular fascial flap is combined with Mustardé and Furnas concha-mastoid sutures. The fascial flap is advanced and covers the sutures to prevent suture extrusion. The advancement of the flap is an additional postauricular support to prevent recurrence. We find this a simple, intrinsically safe otoplasty procedure, with diminished complications, that includes the benefits of both cartilage-cutting and cartilage-sparing methods.

## PATIENTS AND METHODS

From September of 1997 to August of 1999, 51 patients (25 male and 26 female) had otoplasties performed by the senior author using the described technique. There were 45 bilateral procedures and six unilateral procedures, for a total of 96 ears. The patients ranged in age from 4 to 72 years, with a median of 10 years of age. The protrusion of the ear (i.e., the distance from the mastoid skin to the most prominent part of the helix) was measured preoperatively in 40 patients (37 bilateral, three unilateral) and postoperatively in 34 pa-

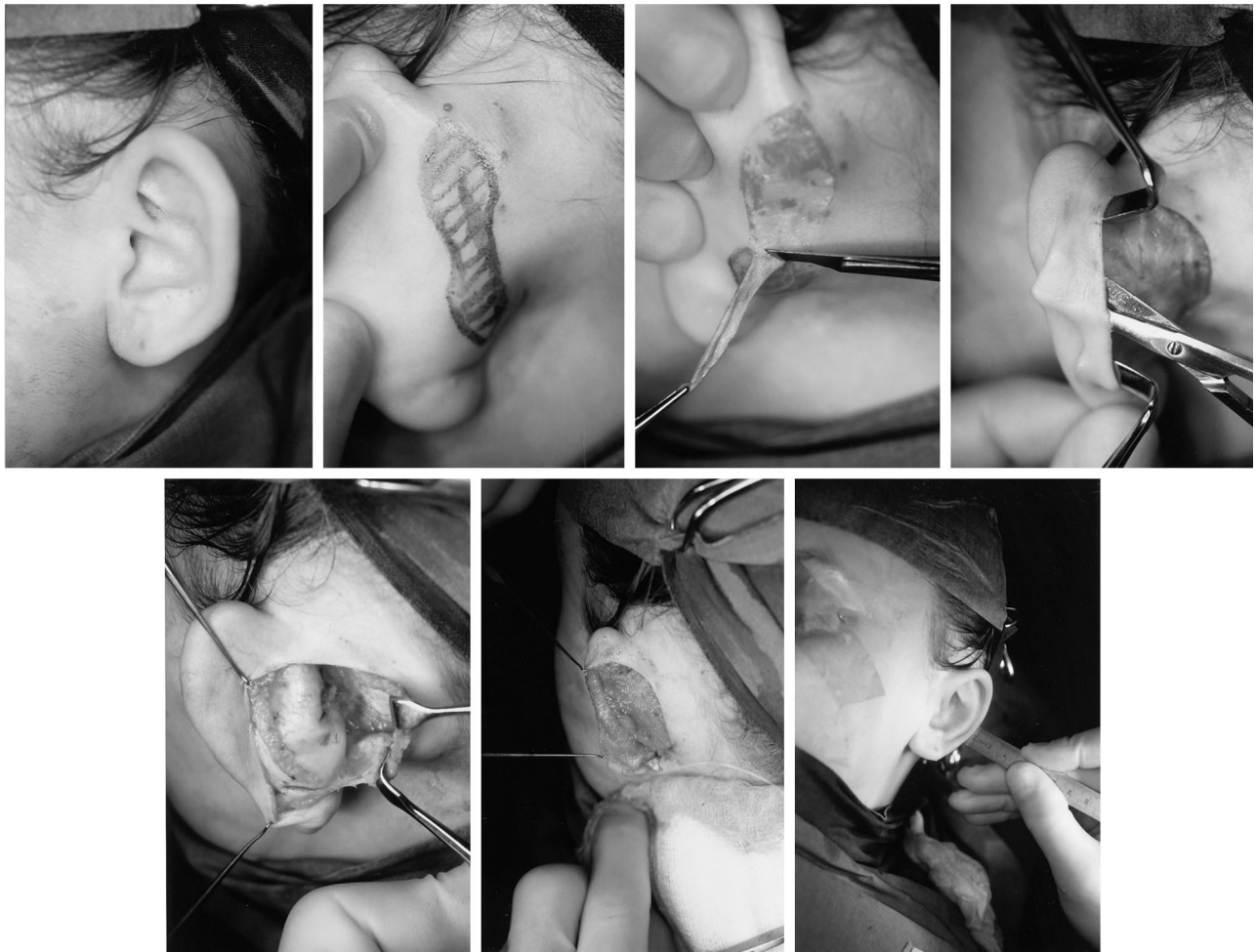

FIG. 1. (*Above, left*) View immediately preoperatively. (*Above, second from left*) The dumbbell-shaped, conservative skin excision is marked. (*Above, second from right*) The dermis and epidermis are excised from the postauricular surface. The subcutaneous tissue and fascia are left on the postauricular surface to be elevated as a fascial flap at a later stage. (*Above, right*) The skin is undermined to the helical rim in the subdermal plane. (*Below, left*) The region of the antihelical fold is marked and the fascia is elevated from the postauricular surface. The free edge follows the curvature of the antihelical fold. The flap is elevated as far medially as the mastoid, thereby allowing plenty of space for the conchal bowl to be rotated medially during placement of concha-mastoid sutures. (*Below, center*) After placement of the Mustardé suture and concha-mastoid sutures, the fascial flap is advanced and sutured to the helical rim, thereby covering the postauricular surface. The excess fascia is then trimmed. (*Below, right*) The immediate postoperative result after closure of the postauricular skin.

tients (31 bilateral, three unilateral). The preoperative protrusion had a mean of 29 mm for both left and right ears (range, 21 to 37 mm for left ears and 20 to 38 mm for right ears).

#### Operative Procedure

First, the postauricular skin is infiltrated with lignocaine and adrenaline 1:200,000. A dumbbell-shaped, conservative skin excision is marked as for any Mustardé or Furnas otoplasty (Fig. 1, *above, left*, and *above, second from left*). The skin excision, however, is limited to the epidermis and dermis only. The subcutaneous layer is left on the posterior aspect of the auricular cartilage (Fig. 1, *above, second from*

*right*). The postauricular skin is undermined to the helical margin to allow placement of Mustardé and Furnas sutures. The difference with this technique compared with other cartilage-sparing methods is that the plane of dissection is at the dermal subcutaneous tissue junction, thereby leaving the subcutaneous tissue on the posterior aspect of the auricular cartilage (Fig. 1, *above, right*). The subcutaneous tissue is then elevated from the auricular cartilage as the fascial flap. A curved radial incision down to the cartilage in the subcutaneous tissue just medial to the antihelical fold allows this flap to be elevated from the auricular cartilage. The flap is elevated as far medially as the mastoid,

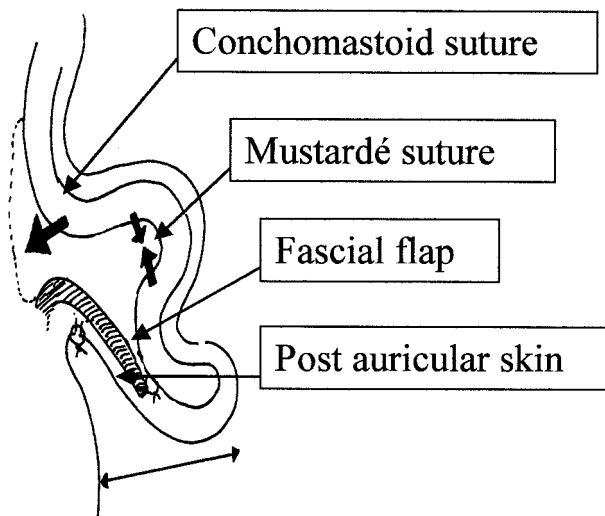


FIG. 2. An illustration of the fascial flap demonstrating the double breasting of skin and fascia.

thereby allowing plenty of space for the conchal bowl to be rotated medially during placement of concha-mastoid sutures (Fig. 1, *below, left*). The Mustardé sutures and concha-mastoid sutures are then placed as previously described.<sup>5,6</sup> We prefer to use 4-0 Ethibond on a round-bodied needle because this has a good hold in the cartilage and does not cut out. During placement of concha-mastoid and Mustardé sutures, the flap must be retracted so that it does not become incorporated in the sutures.

The fascial flap is then advanced back over the posterior aspect of the ear to cover the sutures and is sutured to the posterior part of the helical rim (Fig. 1, *below, center*). Because of the retroposition of the auricle and the advancement of the flap, the excess fascial flap may need to be trimmed. The skin is then closed with subcuticular 5-0 prolene sutures

(Fig. 1, *below, right*). A head bandage is applied for 1 week, although it is not replaced if it becomes dislodged. The flap is a supplementary layer over the sutures to prevent erosion. The skin-suture line in the postauricular sulcus does not overlie the sutures reattaching the flap to the cartilage (lying peripherally). This prevents suture erosion (Fig. 2). Furthermore, the flap advancement acts as additional postauricular support to prevent recurrence.

## RESULTS

Follow-up ranged from 4 months to 30 months, with a median of 11 months. It was assumed that both ears on the same patient were independent variables, and statistical analysis of patients only with preoperative and postoperative measurements were analyzed. Postoperative protrusion was significantly improved to a mean of 19 mm for the left and right ears (range, 11 to 27 mm for left ear and 16 to 27 mm for right ear; paired *t* test,  $p < 0.001$ ). As previously described, we find cartilage-sparing methods produce a normal-looking ear with a natural antehelix.<sup>4,6</sup> The ear of one patient with Erlos Danlos syndrome oozed for 2 days, but despite this, no patient developed a hematoma. No patients developed skin necrosis, and no patients developed suture erosion. Recurrence of deformity occurred with eight ears in six patients (8.3 percent of ears, 11.8 percent of patients). Only two patients requested further surgery (4 percent).

## DISCUSSION

Although a rare complication, it is evident that cartilage-cutting otoplasty may result in irreparable complications because of anterior skin necrosis, cartilage destruction, or cartilage

TABLE I  
Complication Rates for Published Series of Cartilage-Cutting and Cartilage-Sparing Otoplasties

Otoplasty	Author	Year	Patient Number	Method	Recurrence (%)	Suture Erosion (%)	Skin Necrosis (%)	Hematoma (%)	Bleeding (%)
Cartilage cutting	Tan	1986	101	Anterior scoring	9.9	0	NS	NS	8
	Caouette Laberge et al.	2000	500	Anterior scoring	4.4	0	0.6	0.4	2.6
	Calder and Naasan	1994	562	Anterior scoring	8	0	1.4	NS	2
	Chongchet	1962	21	Anterior scoring	10	0	NS	5	NS
	Jeffery	1999	118	Anterior scoring	12.7	0	1.7	3.4	NS
Cartilage sparing	Attwood and Evans	1985	52	Mustardé	0	4.6	NS	NS	2.2
	Tan	1986	45	Mustardé	24.4	15	NS	NS	33
	Rigg	1979	101	Mustardé and Furnas	2	11	NS	NS	NS
	Minderjahn et al.	1980	135	Mustardé	12.3	NS	NS	NS	NS
	Adamson et al.	1991	55	Mustardé and Furnas	6.6	8.4	NS	NS	0.8

NS, not significant.

irregularities secondary to hematoma and infection.<sup>9,10</sup> Cartilage-sparing otoplasty would therefore seem an intrinsically safer procedure because the cartilage is relatively undisturbed and the anterior dissection of the skin is not required. However, recurrence rates have been reported to be unacceptably high and tend to be higher than in cartilage-cutting otoplasty (Table I shows the complication rates for published series of cartilage-cutting and cartilage-sparing otoplasties.). Suture erosion or pain from buried sutures are an additional irritating problem.<sup>4,7,8,11</sup> These problems indicate that cartilage-sparing otoplasty requires further refinement. We feel the addition of the postauricular fascial flap, as an adjunct to cartilage-sparing otoplasty, is a very useful refinement because complications of the sutures are reduced to zero. This is a substantial reduction when compared with the previously reported rate of 4.6 to 15 percent.<sup>7,10-12</sup> Furthermore, recurrence rates are maintained to an acceptable 8 percent of ears, which is on a par with cartilage-cutting methods that have reported recurrence rates between 4.4 and 17.7 percent.<sup>1-3,13,14</sup> However, it is difficult to attribute the reduced recurrence rate solely to the addition of the fascial flap. The elevation of the postauricular fascial flap is a simple and quick additional step that adds an additional vascularized layer between the skin closure and the sutures. Any recurrence that does occur can be addressed, relatively simply, by revisional surgery.

In conclusion, the addition of the postauricular fascial flap to Mustardé and Furnas otoplasty is a useful refinement that reduces suture extrusion rates and may minimize recurrence rates. The refinement maintains a relatively simple, controllable, and intrinsically safe otoplasty that avoids irreparable complications.

Nigel Horlock  
 Department of Plastic Surgery  
 Queen Victoria Hospital  
 East Grinstead  
 West Sussex, RH19 3DZ  
 United Kingdom  
 horlock@nhorlock.freereserve.co.uk

#### REFERENCES

1. Calder, J. C., and Naasan, A. Morbidity of otoplasty: A review of 562 consecutive cases. *Br. J. Plast. Surg.* 47: 170, 1994.
2. Caouette Laberge, L., Guay, N., Bortoluzzi, P., et al. Otoplasty: Anterior scoring technique and results in 500 cases. *Plast. Reconstr. Surg.* 105: 504, 2000.
3. Jeffery, S. L. Complications following correction of prominent ears: An audit review of 122 cases. *Br. J. Plast. Surg.* 52: 588, 1999.
4. Adamson, P. A., McGraw, B. L., and Tropper, G. J. Otoplasty: Critical review of clinical results. *Laryngoscope* 101: 883, 1991.
5. Mustarde, J. C. Correction of prominent ears using buried mattress sutures. *Clin. Plast. Surg.* 5: 459, 1978.
6. Furnas, D. W. Correction of prominent ears with multiple sutures. *Clin. Plast. Surg.* 5: 491, 1978.
7. Rigg, B. M. Suture materials in otoplasty. *Plast. Reconstr. Surg.* 63: 409, 1979.
8. Tan, K. H. Long-term survey of prominent ear surgery: A comparison of two methods. *Br. J. Plast. Surg.* 39: 270, 1986.
9. Reynaud, J. P., Gary-Bobo, A., Mateu, J., and Santoni, A. Chondrites postoperatoires de l'oreille externe: 2 cases from a series of 200 cases (387 otoplasties). *Ann. Chir. Plast. Esthet.* 31: 170, 1986.
10. Adamson, P. A. Complications of otoplasty. *Ear Nose Throat J.* 64: 568, 1985.
11. Attwood, A. I., and Evans, D. M. Correction of prominent ears using Mustarde's technique: An out-patient procedure under local anaesthetic in children and adults. *Br. J. Plast. Surg.* 38: 252, 1985.
12. Minderjahn, A., Huttel, W. R., and Hildmann, H. Mustarde's otoplasty: Evaluation of correlation between clinical and statistical findings. *J. Maxillofac. Surg.* 8: 241, 1980.
13. Chongchet, V. A method of antehelix reconstruction. *Br. J. Plast. Surg.* 16: 268, 1963.
14. Tan, S. T., Abramson, D. L., MacDonald, D. M., et al. Molding therapy for infants with deformational auricular anomalies. *Ann. Plast. Surg.* 38: 263, 1997.